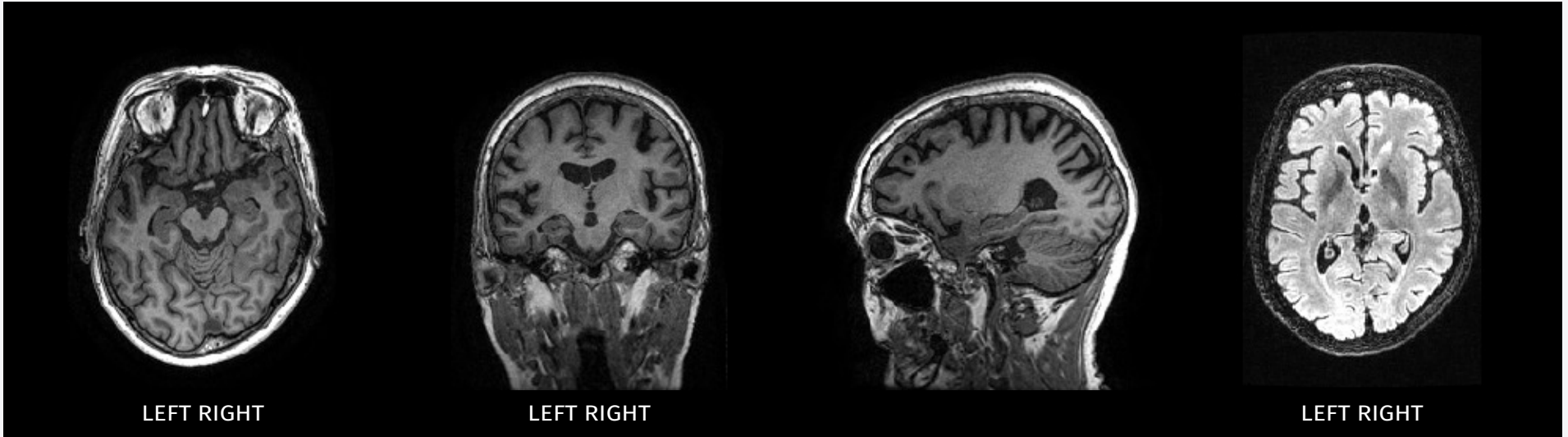


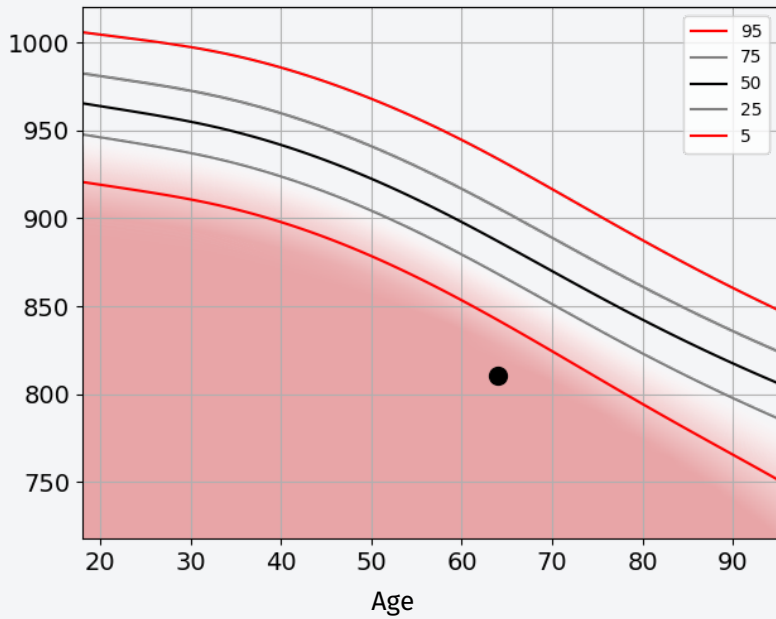
Combinostics Dementia Report Patient

Name: Mary Frontotemporal Personal ID: DEMO-FTD Date of Birth: 1947-07-01 Study date: 2021-11-18

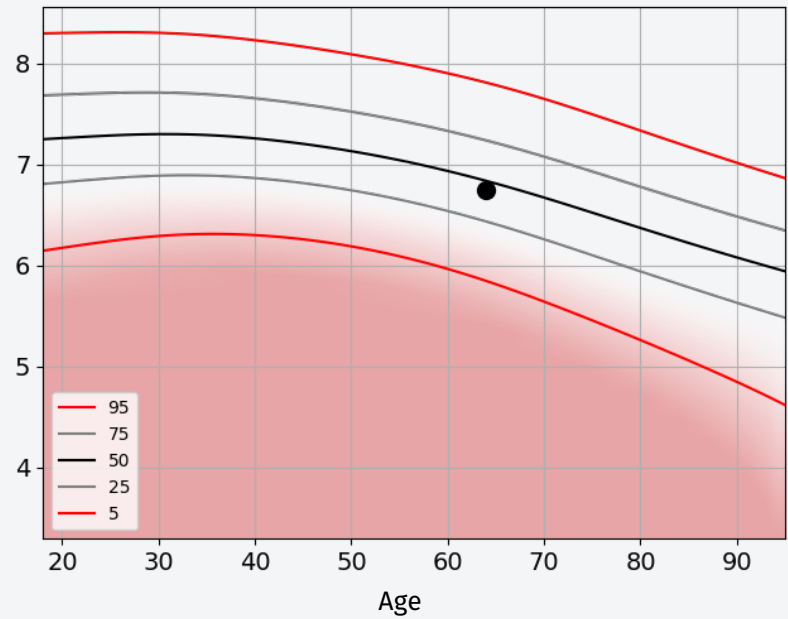


Images

Cerebral gray and white matter volume [ml]



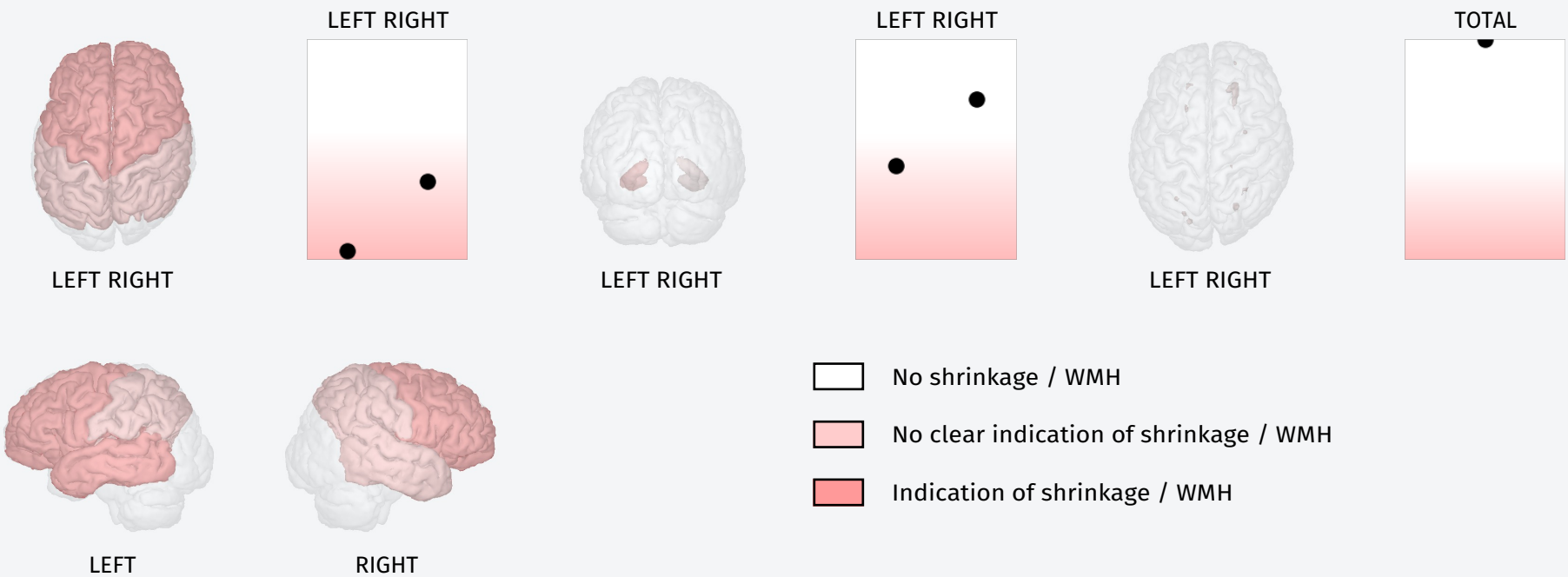
Hippocampus volume [ml]



Shrinkage of cortex

Shrinkage of medial temporal lobe

White matter hyperintensities (WMH)



Comparison to cognitively normal people